

# Evaluation Of The Diagnostic Potential Of A Novel Tomosynthesis System For Chest And Lung Diseases

Eli Attar MD PhD<sup>1</sup>, Ahuva Grubstein MD<sup>1</sup>, Nogah Shabshin MD<sup>3, 4</sup>, Yael Schiffenbauer PhD<sup>5</sup>, Yotam Kimmel BSc<sup>5</sup>, Mordechai Kremer<sup>2</sup> MD PhD

1. Belinson (Rabin medical center) Radiology dept. 2. Belinson (Rabin medical center) pulmonary dept. 3. Haemek Medical Center Radiology dept. 4. Penn University Radiology dept. 5. Nano-x Imaging Ltd.

## Purpose

---

**C**hest Digital Tomosynthesis (DTS) is known for its capability to overcome significant chest radiographs limitations (CXR). It improves detection of chest lesions and their anatomic localization and can exclude false lesions. It has been shown that this technology can reduce the need for CT at a fraction of the radiation dose. DTS also reduces the burden on the radiologists as the number of slices is significantly lower than a standard CT exam. Recently a cold cathode tube with multi tube set-up has made DTS more affordable and accessible. This study aims to evaluate the diagnostic potential of cold-cathode multi-tube DTS for evaluation of the chest compared to CXR.

Rabin Medical Center (RMC), including Beilinson, is one of the most prominent and largest medical facilities in Israel. It is affiliated with the Tel-Aviv Sackler school of medicine.

## Methods

---

**T**he study included 12 patients with known or suspected acute or chronic chest abnormalities that underwent frontal CXR and CT as part of their clinical work-up. After receiving informed consent, patients were scanned using cold-cathode frontal DTS on the same day. Images were evaluated by 2 radiologists with no prior experience in chest DTS, in consensus. They evaluated the CXR, then the DTS while CT served as gold standard.

Evaluation included: presence of lesions (no/questionable/yes) characterization, localization (intra/extrapulmonary/osseous/chest wall), whether the DTS provided additional information, and if the CXR were needed for the interpretation of the DTS (yes/no). Results were analysed for: lesions not seen/questionable on CXR but clearly present on DTS and CT; Questionable/present on CXR but not on DTS and CT, lesions seen on CT only; Accuracy of localization on CXR/DTS.

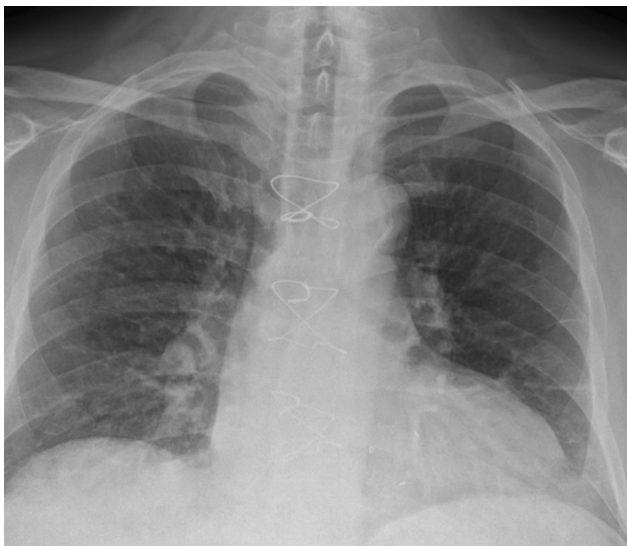
## Results

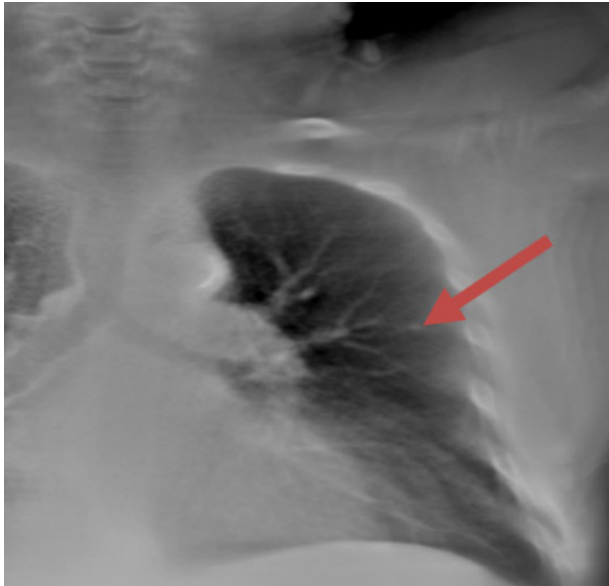---

In all cases DTS added value to the CXR. In 10/12 it found at least 1 radiographically occult lesion (nodule: 7; rib fracture: 1; rib sclerotic lesion: 1, mediastinal lymph node calcifications: 1). Questionable CXR lesions (14, in 8 patients) included nodules (2), enlarged pulmonary hilum (6), mediastinal widening (1), infiltrates (1), interstitial markings (2), line kinking (1), DISH (1) were either accurately confirmed (6), or cleared (8) on DTS. One lesion was questionable on DTS. DTS accurately localized all lesions and characterized hilar lymphadenopathy vs prominent pulmonary arteries in 2 studies with hilar enlargement. Two nodules were seen on DTS retrospectively. Despite no experience in chest DTS, the radiologists were confident that for all studies DTS added significant information and that radiographs were not necessary for DTS interpretation.

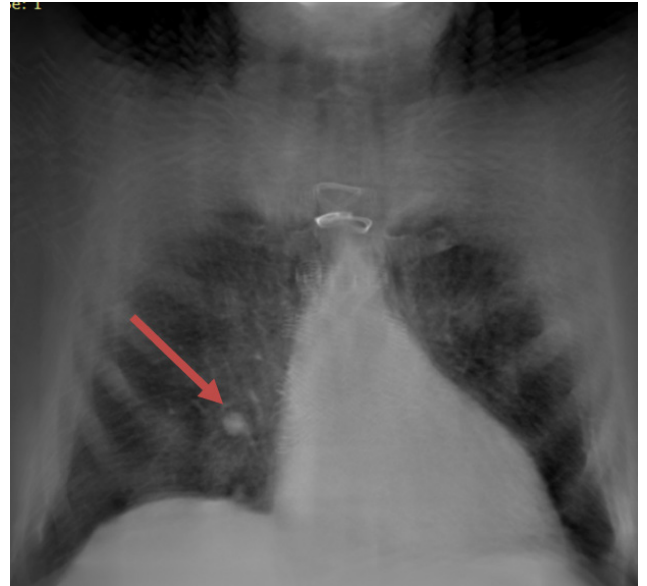
Dr. Ahuva Grubstein, senior chest radiologist in Beilinson said: "I was pleasantly surprised by the sharpness and clarity of the DTS chest images, I was concerned about potential blurriness and am happy that the images provided more relevant clinical information than our standard of care, a chest X-ray".

"The Nanox.ARC system has been implemented in our department for several months now and has really shown to be a valuable addition to the radiology toolbox, enabling us to scan chest patients with ease and efficiency on the Nanox.ARC system yielding great results with substantial advantage over the X-ray system" said Prof. Eli Attar, head of radiology in Beilinson.





A 3mm nodule is seen in the right upper lobe on DTS only (arrow). The nodule is not seen on the 2D radiographs even retrospectively



On a different DTS slice a 1.2 cm nodule is clearly seen (arrow) while on a conventional 2D radiograph it is obscured by the right hilum.

## Conclusion

---

**B**ased on the study results, cold cathode DTS can increase depiction of occult chest lesions, localize, characterize and resolve questionable lesions even without prior radiologist experience.

### **Clinical Application:**

The study shows that cold cathode DTS may have an improved diagnostic accuracy compared to CXR. Its capability to eliminate the need for CT at a fraction of the radiation dose, costs and images per study should be further investigated.